

## REGENARATIVE EFFECT OF VANGA BHASMA IN CADMIUM CHLORIDE INDUCED TESTICULAR DAMAGE - AN EXPERIMENTAL STUDY.

Kavya Shree B. P.<sup>1\*</sup>, Shreeshananda Sharma<sup>2</sup> and Manjula S. N.<sup>3</sup>

<sup>1</sup>\*PG Scholar, Dept. of RS&BK, JSSAMC, Mysuru.

<sup>2</sup>Reader & HOD, Dept. of RS&BK, JSSAMC, Mysuru.

<sup>3</sup>Professor & HOD, Dept. of Pharmacology, JSSCP, Mysuru.

Article Received on  
09 July 2017,

Revised on 29 July 2017,  
Accepted on 19 August 2017,

DOI: 10.20959/wjpps20179-10078

### \*Corresponding Author

**Dr. Kavya Shree B. P.**

PG Scholar, Dept. of  
RS&BK, JSSAMC,  
Mysuru.

### ABSTRACT

Vanga bhasma is a metallic preparation that acts in cases of Sexual debility and Oligospermia, it boosts up dhatuagni's and facilitates the nourishment of all the body tissues and thus augments ojas. Hence used in treatment of male infertility. The present work was undertaken to study the effect of Vanga bhasma on Cadmium Chloride(0.9% in normal saline) induced Testicular toxicity in Wistar rats. Vanga bhasma was administered for 30days and at the end of the study, blood samples, tissue samples and spermatozoans were collected and analyzed for various biochemical and histopathological parameters.

Cadmium chloride produced testicular damage by exhibiting symptoms like shrinkage of Testis. Administering Vanga bhasma prevents oxidative stress, Apoptosis of testicular cells and helps in maintaining normal blood hormonal level(Serum Testosterone) and normal morphology of sperms. Here Ashwagandha churna is taken as a standard drug as it is most widely practised and in knowing superiority of Rasa Aushadis.

**KEYWORDS:** Testicular toxicity, Vanga bhasma(VG), Cadmium chloride, Ashwagandha (AG).

### INTRODUCTION

Fertility is the ability of a person, animal or plant to reproduce by natural means. In humans, infertility is described as a failure to conceive as well as being unable to carry a pregnancy to full term in females and male infertility refers to inability to cause pregnancy in a fertile

female.<sup>[1]</sup> Male infertility accounts for 30-40%, the common causes being defective spermatogenesis, obstruction of efferent duct system, failure to deposit sperm high in the vagina, errors in the seminal fluid. Hence treating this condition is important in medical field.

Testicular Degeneration is most commonly induced by using Cadmium. The major environmental pollutant that enters human body by smoking, fertilizers, plastics and via water etc. It has been established by many workers that cadmium causes a severe testicular degeneration in most mammals with scrotal testes (Pafizek, 1957; Kar & Das, 1960; Gunn, Gould & Anderson, 1963). The experimental model constituted the partially degenerated testis of Wistar rats and to observe the effect of the test drug. Cadmium in any of its soluble form administered at single parental dose is known to selectively degenerate testicular tissue and Vanga bhasma is known to prevent the above effect of cadmium on Testis.

Vanga bhasma is a metallic preparation obtained by incinerating Tin (Stannum) using classical method mentioned in Ayurveda Treatises. It is mentioned in diseases pertaining to Genito urinary tract, specially indicated is Oligospermia, impotency it acts mainly as semen augmentor & Aphrodisiac drug, earlier studies shows the drug acts in normalizing sperm production. Thus it can be said to have a specific role on male genital tract. Acharya caraka mentions – Testis as the origin seat for semen.<sup>[2]</sup>

## **MATERIAL AND METHODS**

### **Experimental animals**

Male Wistar rats weighing 200-250gm were used in the present study. Rats are divided based on their body weight (stratified) into 4 groups- Normal control(group-a), Disease control (group-b), Ashwagandha treated (group-c), Vanga bhasma (group-d) with 6 rats in each group. The rats were obtained from the central animal house facility of JSS Medical college and Hospital, Mysuru and housed in the JSS College of Pharmacy, department of Pharmacology, Mysuru. They are maintained under standard laboratory conditions with natural dark and light cycle. They were allowed free access to standard rat diet and water Ad-libitum.

### **Permission of institutional animal ethics committee**

The protocol of the work mentioning details of the experimental technique, justification of the use of animals, number of animals to be used, type of Anaesthesia, surgical procedure to

be used were reviewed and approved by the Institutional animal ethics committee, JSS Collge of Pharmacy, Mysuru, Proposal no.209/2016.

### **Drugs preparation, dose and duration of treatment**

Carboxy methyl cellulose- A CMC solution of 0.5% was prepared. 500mg of CMC powder was weighed and triturated in potable water using mortar and pestle. This was transferred into a volumetric flask measuring 100ml and volume was made up. As bhasma are insoluble suspension was made using this.

Vanga bhasma- This is also known as Dasha puti Vanga bhasma by Acharya Madhava in the text Ayurveda prakasha. The raw Vanga was obtained from local market and was subjected to classical shodana done using Nirgundi Swarasa, Jarana done using Ashwatta and Chinchatwak churna followed by Marana using Shodita Haratala and subjected to puta for 10 times. After passing all classical bhasma pareeksha like Rekhapurnatwa, Nishchandratwa, Varitara, Uttama, Apunarbhava and Analysis of vanga bhasma was done in Vijnana bhavan, university of Mysuru.

Ashwagandha churna(*Withania somnifera*)- The dry root of Ashwagandha was purchased from the local market. This was pounded in mortar and powder was prepared. This was passed through sieve no. 100 to obtain fine powder. The drug was tested using Organo leptic characters.

Animal dose were calculated from human dose per day according to Rat dose conversion formula based on body surface area ration. Animal dose of Cadmium chloride 1mg/kg body weight in 0.9% of normal saline in a single dose, Vanga bhasma is 25.66mg/kg body weight and Ashwagandha churna it was 1,233.8 mg/kg body weight. The doses and concentration for Vanga bhasma and Ashwagandha churna suspension was prepared using 0.5% of CMC solution, were administered orally to rat for 30days.

### **Experimental design**

After 7 days of acclimatisation, on 8<sup>th</sup> day Cadmium chloride was given in 0.9% normal saline for all 3 groups b, c & d intra peritoneal. From 9<sup>th</sup> day to 38<sup>th</sup> day treatment was given to group-c with Ashwagandha churna and group-d with Vanga bhasma orally. Six hours after the last treatment on day 38<sup>th</sup> of the protocol for groups a-d, all the rats from all groups were anesthetized with light diethyl ether and 2 ml blood samples were collected using a capillary

tubes using retro orbital method into plain 2 ml sterile centrifuge tubes, where they were allowed to clot for 15 min at room temperature. Samples were centrifuged at 4000 rpm for 10 min to obtain the serum, which was used to determine the levels of testosterone. Further, all the animals in all groups were sacrificed by decapitation, and both testes were removed and transferred into Petri dishes. The adipose tissues, connective tissues and blood vessels were removed from them. The epididymis was then removed and sperms are collected from Cauda epididymus for sperm morphology. The testes were removed and weighed. The right testis from each rat in all groups was given for Testes histo-pathological study. And the left testis was used for determination the oxidants by estimating Glutathione reductase and TBARS.

### **Sperm morphology**

A drop of Eosin stain was added to the sperm suspension, which was kept for 5 min, at 37°C. Then, a drop of sperm suspension was placed on a clean slide and was gently spread to make a thin film. The film was air dried and then observed under a compound microscope for changes in sperm morphology at 400x magnification according to the method of Feustan *et al.*<sup>[3]</sup> The following sperm abnormalities were counted in two separate fields in each of the sperm samples described above: absence of head, absence of tail, tail bending, tail coiling, mid-piece curving and mid-piece bending.

### **Preparation of Testis homogenate**

For biochemical estimation 10% w/v Testis homogenate was prepared in phosphate buffer (pH 7.4,) using Telfon homogenizer. The clear supernatant, obtained after centrifugation at 3000 rpm for 15 min, was used to estimate Thiobarbituric acid reactive substances (TBARS), reduced Glutathione (GSH) level.

### **Estimation of Thiobarbituric Acid Reactive Substances (TBARS)**

The quantitative measurement of thiobarbituric acid reactive substances (TBARS), an index of lipid peroxidation in brain was performed according to the method of Okhawa *et al.*, 1979.<sup>[4]</sup> 0.2 ml of supernatant of homogenate was pipetted out in a test tube, followed by addition of 0.2 ml of 8.1% sodium dodecyl sulphate, 1.5 ml of 30% acetic acid (pH 3.5), 1.5 ml of 0.8% of thiobarbituric acid and the volume was made up to 4 ml with distilled water. The test tubes were incubated for 1 h at 95°C, then cooled and added 1 ml of distilled water followed by addition of 5 ml of n-butanol-pyridine mixture (15:1 v/v). The tubes were centrifuged at 4000 rotations for 10 min. The absorbance of developed pink color was measured spectrophotometrically (DU 640B spectrophotometer, Beckman Coulter Inc., CA,

USA) at 532 nm. A standard calibration curve was prepared using 1-10 nm of 1, 1, 3, 3-tetra methoxy propane. The TBARS value was expressed as nanomoles per mg of protein.

### **Estimation of Reduced Glutathione (GSH)**

The reduced glutathione (GSH) content in tissue was estimated using method of Beutler *et al.*, 1963.<sup>[5]</sup> The supernatant of homogenate was mixed with trichloroacetic acid (10% w/v) in 1:1 ratio. The tubes were centrifuged at 1000 rotations for 10 min at 4°C. The supernatant obtained (0.5 ml) was mixed with 2 ml of 0.3 M disodium hydrogen phosphate. Then 0.25 ml of 0.001 M freshly prepared DTNB [5, 5'-dithiobis (2-nitrobenzoic acid) dissolved in 1% w/v sodium citrate] was added and absorbance was noted spectrophotometrically (DU 640B spectrophotometer, Beckman Coulter Inc., CA, USA) at 412 nm. A standard curve was plotted using 10-100 µM of reduced form of glutathione and results were expressed as micromoles of reduced glutathione per mg of protein.

### **Histopathological studies**

Specimens of the testes in experimental groups were fixed in 10% neutral buffered formalin, dehydrated in ascending concentrations of ethyl alcohol (70–100%) and then processed further and histopathological slides were prepared and stained using hematoxylin and eosin stain and observed for changes in cellular architecture using standard procedures.

### **Statistical analysis**

Statistical analyses were performed by using the Graph Pad Prism statistical software package (version 5). The values are presented as means with standard error mean (Mean ± SEM). Normality and homogeneity of the data were confirmed before ANOVA and differences among the experimental groups were assessed by one-way ANOVA followed by Post Hock Tukey's multiple comparison test.

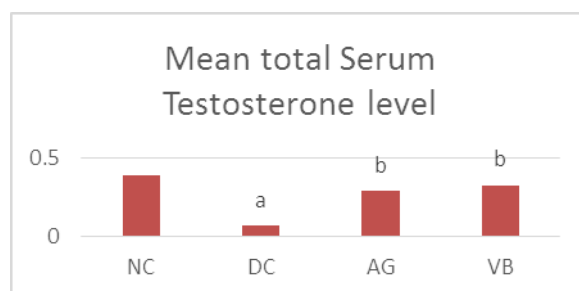
## **OBSERVATIONS AND RESULTS**

### **SERUM TESTOSTERONE**

Serum testosterone levels (total) of normal and experimental animals is shown in Table no.1 We can see the highly significant increase of hormonal levels in VB with p value <0.01 and significant increase of hormonal levels in AG group with p value <0.05.

**Table 1: Effect of VB in total serum Testosterone levels in CdCl<sub>2</sub> challenged rats.**

Group	Serum testosterone ng/dl
NC	0.3950±0.06840
DC	0.0666±0.00105
AG	0.2883±0.04792
VB	0.3283±0.04983



All values are expressed as Mean±SEM, n=6. Data were analysed by one- way ANOVA followed by post Tukey's multiple comparison test.

*ap*<0.05 when compared to NC

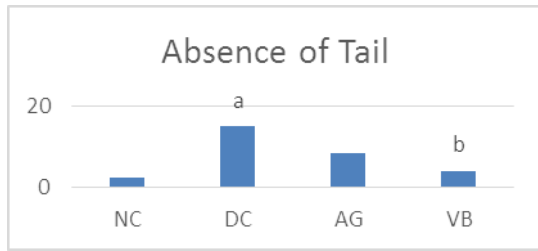
*bp*<0.05 when compared to DC

### **SPERM MORPHOLOGY**

The results obtained from the morphological assessment of sperms indicated that the total percentages of abnormal sperms are in diseased control and Ashwagandha treated group are more. The majority of the significant abnormalities included increased percentages of absence of tail, absence of head and tail bending. The table no.2 shows significant difference between the normal control with diseased and Ashwagandha treated group. The vanga bhasma treated group shown highly significant difference compared to AG.

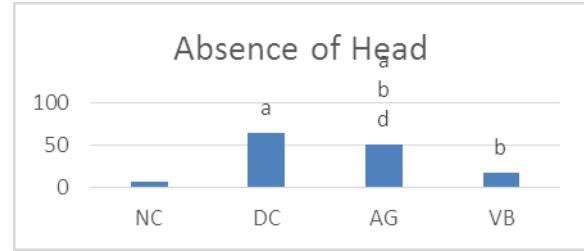
**Table: 2: Effect of VB in % of sperm morphology in CdCl<sub>2</sub> challenged rats.**

GROUPS	Absence of tail	Absence of head	Tail bending	Tail coiling	Normal forms
NC	2.500±1.118	6.667±2.108	10.83±2.386	4.167±1.537	73.33±1.667
DC	15.00±2.887	64.17±2.002	62.50±4.958	17.50±2.141	10.83±2.386
AG	8.333±1.054	50.83±3.962	55.33±2.472	14.17±2.386	19.17±2.386
VB	4.167±1.537	17.50±3.819	16.67±2.472	6.667±1.667	67.33±2.028



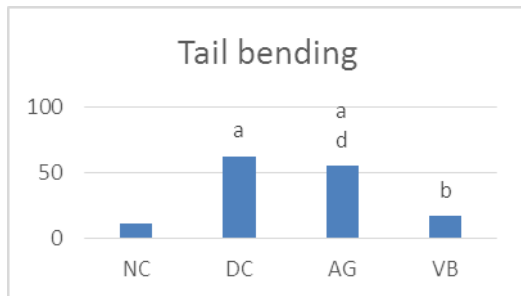
All values are expressed as Mean±SEM, n=6. Data were analysed by one-way ANOVA followed by post Tukey's Multiple comparison test.

ap<0.001 when compared to NC  
bp<0.01 when compared to DC



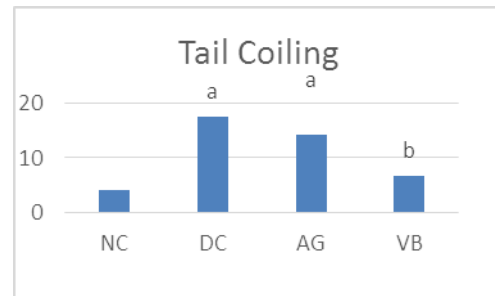
All values are expressed as Mean±SEM, n=6. Data were analysed by one-way ANOVA followed by post Tukey's Multiple comparison test.

ap<0.001 when compared to NC  
bp<0.001 when compared to DC  
dp<0.001 when compared to VB



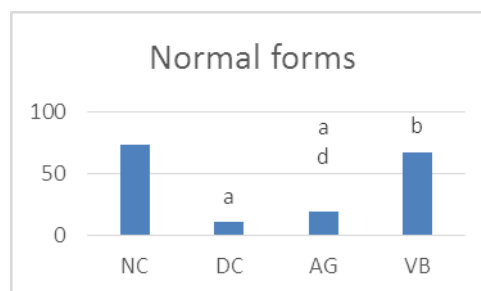
All values are expressed as Mean±SEM, n=6. Data were analysed by one-way ANOVA followed by post Tukey's multiple comparison test.

ap<0.001 when compared to NC  
bp<0.001 when compared to DC  
dp<0.01 when compared to VB



All values are expressed as Mean±SEM, n=6. Data were analysed by one-way ANOVA followed by post Tukey's multiple comparison test.

ap<0.01 when compared to NC  
bp<0.01 when compared to DC



All values are expressed as Mean±SEM, n=6. Data were analysed by one-way ANOVA followed by post Tukey's multiple comparison test.

$ap < 0.001$  when compared to NC

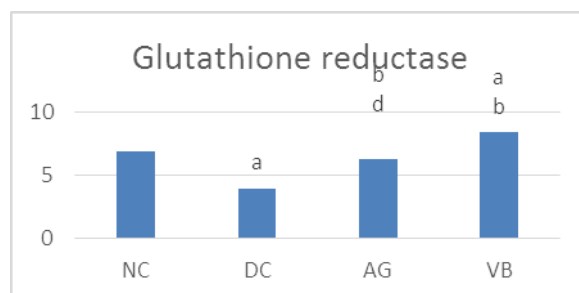
$bp < 0.001$  when compared to DC

$dp < 0.001$  when compared to VB

### EVALUATION OF ENDOGENOUS ANTIOXIDANT ENZYMES

The levels of lipid peroxidation and glutathione reductase are significantly decreased ( $p < 0.001$ ) levels of glutathione reductase in the testes tissue homogenate were observed in diseased control group when compared to normal group, while an increased level of lipid peroxidation was seen in treatment group vanga bhasma with  $p$  value  $< 0.01$  when compared with normal group. Where as decreased TBA levels seen in vanga bhasma with  $p$  value  $< 0.001$  & AG treated groups with  $p$  value  $< 0.01$  when compared to diseased control.

Group	Glutathione reductase (U/mg)
NC	6.904±0.3339
DC	3.971±0.1541
AG	6.220±0.3220
VB	8.441±0.2364



All values are expressed as Mean±SEM,  $n=6$ . Data were analysed by one-way ANOVA followed by post Tukey's multiple comparison test.

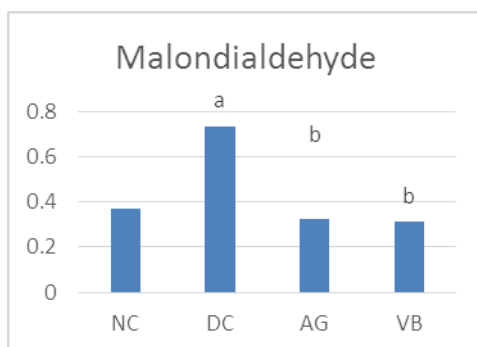
$ap < 0.01$  when compared to NC

$bp < 0.001$  when compared to DC

$dp < 0.001$  when compared to VB

Group	MDH n/molgm of protein
NC	0.3692±0.0594
DC	0.7358±0.0711
AG	0.3248±0.0708
VB	0.3127±0.0372





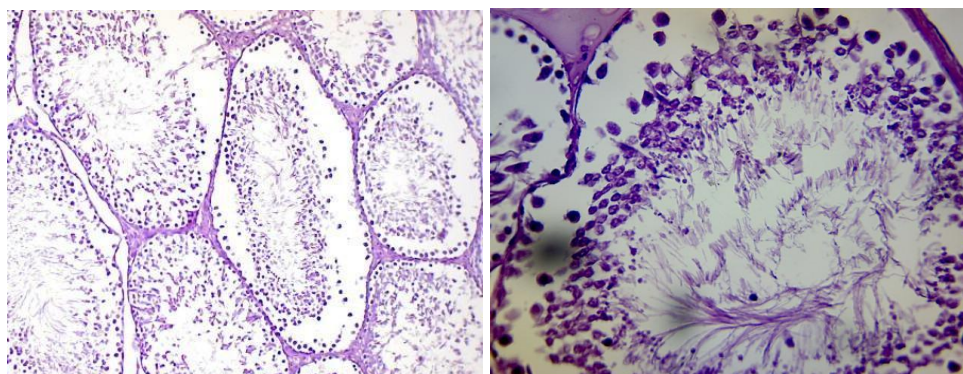
All values are expressed as Mean±SEM, n=6. Data were analysed by one- way ANOVA followed by post Tukey's multiple comparison test.

*ap*<0.01 when compared to NC

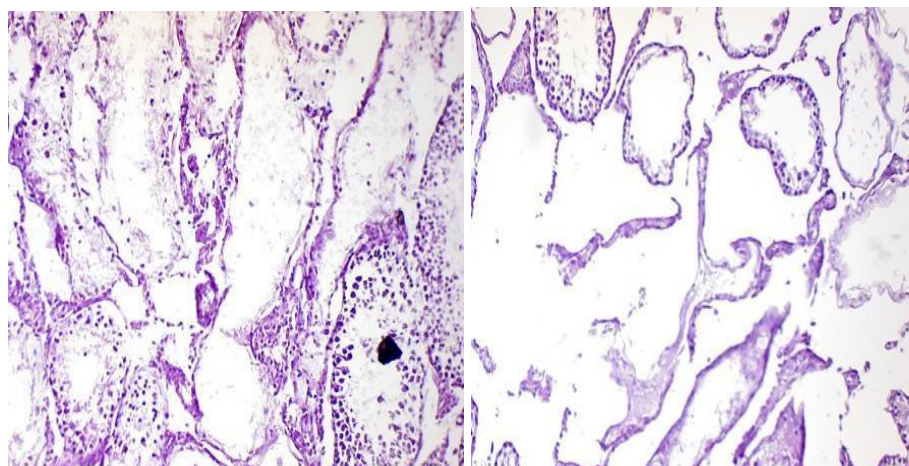
*bp*<0.01 when compared to DC

### HISTO-PATHOLOGICAL REPORTS

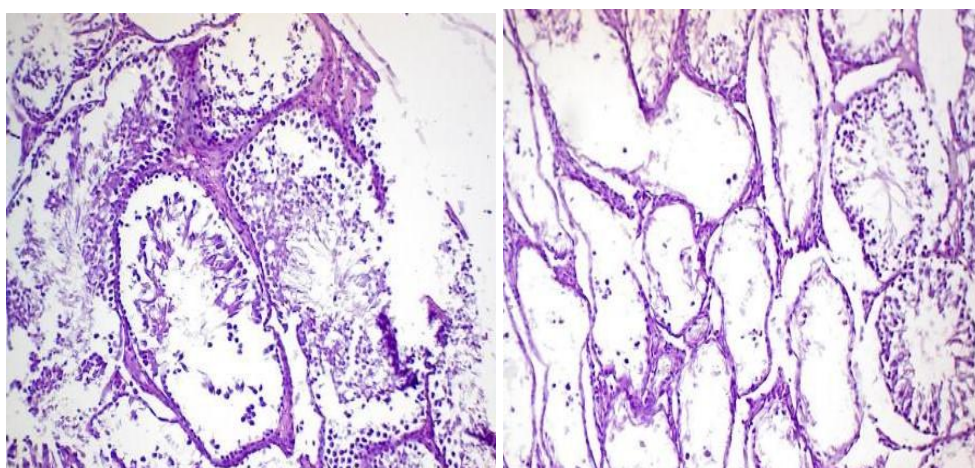
- The histo-pathological reports of the Normal group- sections show testicular tissue displaying normal spermatogenesis in >75% of the seminiferous tubules.
- Diseased control showing- sections of testicular tissue displaying spermatogenesis in <10%- 20% of the seminiferous tubules. Most tubules show degeneration of germ cells with maturation arrest at primary spermatogonia level, areas of necrosis also noted.
- Treatment group (Ashwagandha group) – Displaying normal spermatogenesis in 30-40% of seminiferous tubules. Few tubules show degeneration of germ cells and maturation arrest with absence of mature sperms. Some tubules show complete absence of germ cells in the tubules.
- Treatment group (Vanga bhasma) - sections show testicular tissue with normal spermatogenesis in 60-70% of seminiferous tubules. Few tubules show degeneration of germ cells.



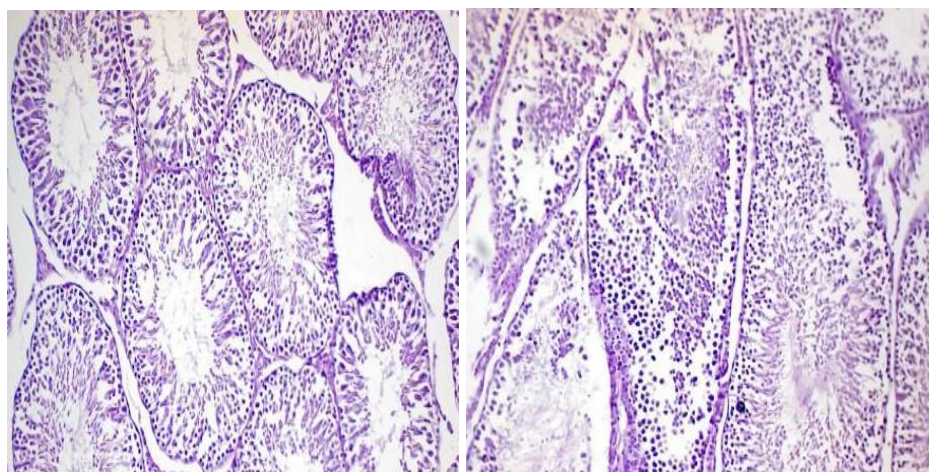
Normal control- slide 1 & 2.



Slide -diseased control 3 & 4.



Slide - Ashwagandha treated 5 & 6.



Slide - Vanga bhasma treated 7&8.

## DISCUSSION

Rasaushadis are known for its quick action in minimal dosage and hence being used since centuries. Importance of progeny has been explained since Vedic period in attaining salvation spiritually or naturally in continuing human population. Infertility is such a condition where above cannot be achieved and hence treatment for this is important since time immortal. Male infertility is prime factor as it is vastly affected by life style, food habits and changed environmental conditions. Vanga bhasma is a metallic preparation that acts in cases of Sexual debility and Oligospermia. The present animal experiment was conducted to know the efficacy and pharmacological aspects of the drug. The study was conducted with 24 wistar rats divided into 4 groups with 6 each. The experimental model includes induction of toxicity followed by treatment for 30 days. Testicular damage was induced using Cadmium chloride in normal saline at 0.9% concentration IP single dose. The treatment was done using Vanga bhasma taking Ashwagandha as a standard drug. The samples were collected for assay like Serum testosterone, lipid peroxidation like TBARS & GSH, Sperm morphology and histopathological studies. This was analysed using statistical software graph pad prism-5.

El-Ashmawy and Youssef<sup>[6]</sup>, who demonstrated that a single dose of CdCl<sub>2</sub> induced severe necrosis and degeneration of seminiferous tubules with complete loss of spermatogenic cell layers and absence of centrally located spermatozoa in untreated groups.

The interactions of a complex network of causes in the testis is probably a result of CdCl<sub>2</sub> testicular toxicity. The concentration of the cadmium chloride varies the amount of damage in accordance. It is observed that 1mg/kg body wt. is sufficient to cause complete necrosis and destruction of germ cells histo-pathologically. Understanding their precise mechanism of testicular damage induced by CdCl<sub>2</sub> remains unclear, in spite of well recognized toxicity. In the current study, CdCl<sub>2</sub> administration increased oxidative stress (increased TBA and decreased GSH) treated rats, which was associated with the observed testicular damage i.e destruction of germinal cells, necrosis and semen of poor quality.

The Spermatogenesis in rats is affected by the mechanisms like oxidative stress and apoptosis of cell which produces abnormal and less number of sperms. Zemjanis<sup>[7]</sup> reported that spermatozoa abnormalities such as absence of tail, absence of head, tail coiling and mid-piece bending are considered to reflect disturbances in spermatogenesis, whereas secondary abnormalities such as abnormal acrosome are believed to arise after spermatogenesis is completed due to epididymal dysfunction. It has been reported that oxidative stress affects the

sperm cell via interference with the membrane fluidity, which is the main factor for sperm motility and fusion with the oocyte.<sup>[8]</sup> In addition, Bench et al<sup>[9]</sup>, reported that CdCl<sub>2</sub> has a detrimental effect on testicular function (stages of spermatogenesis) that could result in reduced sperm production leading to reduced male fertility.

All the groups showed significant increase in body weight. So it can be inferred that either the test drug or treatment drug not interfered in BMR of the animals and the results are restricted for reproductive system only.

The comparison of testes weight revealed there was increase in the testes weight of treated group with Vanga bhasma significantly as compared with diseased control. This showed protective activity of the drug significantly even when compared with standard Ashwaganda group. It was reported that CdCl<sub>2</sub> administration significantly increased Nitric oxide production<sup>[10]</sup>, leading to a decrease in testosterone synthesis in the Leydig cells by acting centrally on the pituitary gland and inhibiting LH secretion.<sup>[11,12]</sup>

The elevated levels of LPO in the testicular tissue may be due to accumulation of the lipid peroxides in the germinal cells by free radicals as a result of oxidative stress. There was significant difference with increased TBA and decreased Glutathione levels in Cadmium chloride induced group, suggest that the treated groups of trial drugs have a significant effect in reduction of free radicals by inhibiting oxidative stress and maintaining membranal integrity, similar to the standard drug AG.

## CONCLUSION

Vanga bhasma reverses Testicular damage in Cadmium Chloride treated Wistar Rats. The drug is effectively beneficial in oxidative stress, Apoptosis of testicular cells and helps in maintaining normal Serum Testosterone levels and normal morphology of sperms. The study suggests superiority of Rasa aushadis in comparison with Kashta aushadi.

## REFERENCES

1. Dutta.D.C, Text book of Gynaecology, Konar Hiralal, 6<sup>th</sup> edition 2013, New central book agency(p) limited 8/1 Chintamani Das Lane, Kolkata-700009, pp 220-226.
2. Agnivesha, Caraka samhita, Translated by Sharma.P.V, 2011, Vol I, Chowkhamba Ayurveda Pratishtan, Varanasi, Vimana sthana, pp-434.

3. Feuston MH, Bodnar KR, Kerstetter SL, Grink CP, Belcak MJ, Singer EJ. Reproductive toxicity of 2-methoxyethanol applied dermally to occluded and nonoccluded sites in male rats. *Toxicol Appl Pharmacol*, 1989; 100: 145–161. [Medline] [CrossRef]- sperm morphology.
4. Ohkawa H, Ohisini N, Yagi k, Assay for lipid peroxides in animal tissues by Thiobarbituric acid reaction, *Anal Biochem*, 1979; 95: 351-358.
5. Beutler, E, Duran O and Kelly.B.M, improved method for the determination of blood glutathione, *J Lab Clin Med*, 1963; 61: 882.
6. El-Ashmawy IM, Youssef SA. The antagonistic effect of chlorpromazine on cadmium toxicity. *Toxicol Appl Pharmacol*, 1999; 161: 34–39. [Medline] [CrossRef].
7. Zemjanis R. Collection and evaluation of semen. In: *Diagnostic and Therapeutic Technique in Animal Reproduction*. 2<sup>nd</sup> ed. Baltimore: William and Wilkins Company; 1970; 139–153.
8. Aitken RJ. Free radicals, lipid peroxidation and sperm function. *Reprod Fertil Dev*, 1995; 7: 659–668. [Medline] [CrossRef].
9. Bench G, Corzett MH, Martinelli R, Balhorn R. Cadmium concentrations in the testes, sperm and spermatids of mice subjected to long-term cadmium chloride exposure. *Cytometry*, 1999; 35: 30–36. [Medline] [CrossRef].
10. Waisberg M, Joseph P, Hale B, Beyersmann D. Molecular and cellular mechanisms of cadmium carcinogenesis. *Toxicology*, 2003; 192: 95–117. [Medline] [CrossRef].
11. Dobashi M, Fujisawa M, Yamazaki T, Okuda Y, Kanzaki M, Tatsumi N, Tsuji T, Okada H, Kamidono S. Inhibition of steroidogenesis in Leydig cells by exogenous nitric oxide occurs independently of steroidogenic acute regulatory protein (star) mRNA. *Arch Androl*, 2001; 47: 203–209. [Medline] [CrossRef].
12. Samy.M.Eleawa, Mahmoud A Alkateeb, Fahaid H Alhasem, Ismaeel Bin Jaliah, Hussain F Sakr, Hesham M Elrefaey, Abbas O Elkarib, Riyad M Alessa, Mohammad A Haidara, Abdulla S Abdulla and Mohammad A Khalil. Resvetrol reverses Cadmium Chloride-induced Testicular damage and subfertility by Downregulating p53 and Bax and Upregulating Gonadotropins and Bcl-2 gene Expression. *Journal of Reproductive and Development*, 2014; 60: 2.